症 例

Successful Treatment of a Patient with Delayed-onset Paraplegia after Thoracic Endovascular Aortic Repair

Taketo Nakamura*, Tokuhiro Yamada*, Tadashi Matsuura*, Katsuaki Tanaka*, Tomoharu Funao*, Kiyonobu Nishikawa*

Abstract

A 60-year old man developed paraplegia three hours after thoracic endovascular aortic repair under general anesthesia for distal aortic arch aneurysm. This delayed-onset paraplegia was suspected to be due to a steal effect on the spinal small end arteries. The symptom was successfully alleviated by rapid lumbar cerebrospinal fluid drainage

Introduction

Postoperative paraplegia has been a main complication of thoracic aortic aneurysm (TAA) surgery. We report a patient who developed delayed-onset paraplegia three hours after thoracic endovascular aortic repair (TEVAR) for distal TAA, which could be recovered by quick institution of lumbar cerebrospinal (CSF) drainage.

Case Report

The patient was a 60-year-old man (height, 165 cm; weight, 77 kg), who had received descending aortic graft replacement at the age of 45. A saccular aneurysm near the graft enlarged gradually over 2 years (**Fig. 1**). We selected TEVAR for distal aortic arch aneurysm below the left subclavian artery under general anesthesia. The patient did not exhibit any neurological deficits before this procedure. The relevant medical history included hemodialysis for 5 years and well-controlled hypertension. The findings of electrocardiography, transthoracic echocardiography, and coronary angiography were normal. The great anterior radiculomedullary artery was identified at the tenth thoracic vertebral (T10) level by three-dimensional computed tomography (CT).

Standard monitoring was performed in TEVAR, including invasive arterial blood pressure (ABP), electrocardiography by lead II, and pulse oximetry. ABP was 122/68mmHg and the heart rate (HR) was 76 beats/min. A 20-gauge cannula was placed in

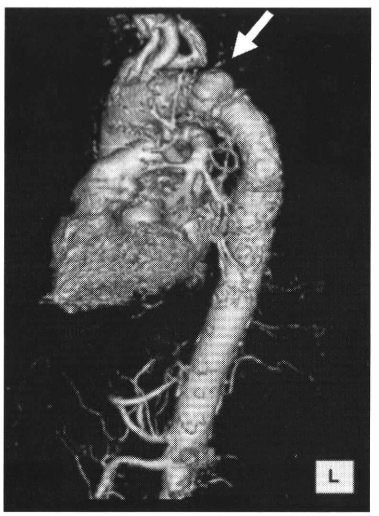

Figure 1 This figure shows the three-dimensional contrast computed tomography image of our patient. A saccular aneurysm, which an arrow sign indicated, is located between the left subclavian artery and the origin of the previous graft.

*Department of Anesthesiology Osaka City University Graduate School of Medicine, Osaka, Japan

a right forearm vein, and anesthesia was induced with a bolus injection of 100mg propofol and a continuous infusion of 0.25μg·kg^{-1}·min^{-1} remifentanil simultaneously. A 20-gauge cannula was inserted in the right radial artery; tracheal intubation was performed after administering 8mg of vecuronium. Anesthesia was maintained with sevoflurane (end-tidal concentration, 1.2～1.5%) in a mixture of oxygen and air (inspired oxygen fraction was 40%) and remifentanil (0.05～0.2μg·kg^{-1}·min^{-1}). Partial pressure of oxygen was maintained over 200 mmHg and that of carbon dioxide was 35～40mmHg in the arterial blood. We administered 5000units of heparin before insertion of the catheter via the right femoral artery and kept activated coagulation time (ACT) over 300s. The graft was deployed below the left subclavian artery and the end of the graft was free from the great anterior radiculomedullary artery. Mean arterial pressures (MAP) had been maintained above 80mmHg throughout the operation, except during the stent attachment to prevent the migration. ACT was restored to 127s by 5ml of protamine sulfate, the operation completed in 5h 46min. The amount of blood loss summed up 150mL and the amount of fluid infusion was 720mL. The patient was emerged from anesthesia, extubated in the operating room, and admitted to the intensive care unit (ICU); he did not show any signs of neurological deficits.

Although MAP was maintained over 90mmHg without hypertensive treatment and the patient did not receive hemodialysis after the admission of ICU, paraplegia suddenly appeared 3h after the admission; there was a marked loss of muscle strength and decrease in sensation below the L1 lumbar vertebrae in the right lower extremity and below L2 in the left. Noncontrast CT did not reveal migration of the stent and acute dissection of the thoracic aorta. Since dopamine-induced arterial pressure augmentation did not ameliorate paraplegia up to 120mmHg on MAP, lumbar CSF drainage was quickly instituted to improve spinal cord perfusion and a catheter was placed in the lumbar intervertebral space between the fourth and the fifth lumbar vertebrae (L4/5) with confirmation that ACT and blood platelet count were kept in normal range. CSF outflow run out drastically at the puncture, not allowed to measure CSF pressure. Muscle strength improved to manual muscle testing (MMT) grade 4 and tactile sensation returned to normal soon; however, thermal sensation was lost below L2 on the right. CSF drainage was placed at 10cm H_2O from the external ear, amounted to 170mL in two days.

On the first postoperative day, the patient completely recovered from the loss of strength and tactile sensation, but he did not recover from thermal sensation abnormality below L2 on the right lower extremity. Aortic angiography did not show an occlusion of the left subclavian artery and the great anterior radiculomedullary artery caused by the stent on the seventh postoperative day.

Discussion

TAA procedure involving the distal two-thirds of the descending aorta has been regarded to have a high risk of spinal cord injury (SCI) for two decades[1]. Actually, the risk factors for ischemic SCI are as follows: Crawford type II thoracoabdominal aortic aneurysm, chronic renal insufficiency, poor collateral blood flow of the spinal cord, previous aortic reconstructive surgery, and low perfusion of the left subclavian artery[1,2]. Protective interventions, such as CSF drainage, epidural cooling, distal aortic perfusion, and monitoring motor evoked potential have been recommended in high risk patients[3~5]. Although our patient was in accordance with the two risk factors, spinal protective adjuncts were not required because the procedure did not involve both of the left subclavian artery and the great anterior radiculomedullary artery, and especially, spinal bleeding complications had to be prevented from hemodialysis.

Delayed-onset paraplegia emerges from a few hours to days after operation, and it has an incidence rate of 2.7% after TEVAR[2]. The major cause is considered as hypotension in the early postoperative period[6], and it should be treated promptly augmenting arterial pressure. However, it is assumed that

hypertensive treatment is less effective in improvement in the spinal cord perfusion than CSF drainage, if CSF pressure was elevated with tremendous acceleration. Spinal cord ischemia might produce spinal edema to rise CSF pressure drastically; a 4mmHg decrease in CSF pressure contributes to about 19% increase in the estimated spinal cord perfusion[7]. It is highly recommended that spinal cord perfusion pressure be kept greater than 70mmHg and CSF drainage be intervened into surgical procedures with cross-clamp. Although it is uncertain whether TEVAR needs CSF drainage or not[8], high risk cases with comorbidities such as mentioned above should be placed for CSF drainage to maintain spinal cord perfusion due to a limitation of an arterial augmentation as this case did. Since hypotension and occlusion of the great anterior radiculomedullary artery were not observed in this patient, the delayed-onset paraplegia was suspected to be a steal effect on spinal small end arteries. The graft might produce atheromatous debris to occlude the end small arteries and generate retrograde flow into dilated visceral vessels through a spinal collateral network in a normothermic condition, which often overlapped with postoperative rewarming[6]. This assumption might be associated with an insufficient restoration of the distant lateral spinothalamic tract, which was responsible for thermal sensation.

In summary, we successfully managed delayed-onset paraplegia not associated with hypotension 3h after TEVAR. The patient's neurological symptoms were successfully reversal by CSF drainage, which was highly effective in maintaining spinal cord perfusion in some cases with extremely elevated CSF pressure.

References

1) Ackerman LL, Traynelis VC: Treatment of delayed-onset neurological deficit after aortic surgery with lumbar cerebrospinal fluid drainage. Neurosurgery 2002; 51: 1414-22.
2) Buth J, Harris PL, Hobo R, et al: Neurologic complications associated with endovascular repair of thoracic aortic pathology: Incidence and risk factors. a study from the European Collaborators on Stent/Graft Techniques for Aortic Aneurysm Repair (EUROSTAR) registry. J Vasc Surg 2007; 46: 1103-11.
3) Estrera AL, Rubenstein FS, Miller CC 3rd, et al: Descending thoracic aortic aneurysm: surgical approach and treatment using the adjuncts cerebrospinal fluid drainage and distal aortic perfusion. Ann Thorac Surg 2001; 72: 481-6.
4) Safi HJ, Miller CC 3rd, Huynh TT, et al: Distal aortic perfusion and cerebrospinal fluid drainage for thoracoabdominal and descending thoracic aortic repair: ten years of organ protection. Ann Surg 2003; 238: 372-81.
5) Azizzadeh A, Huynh TT, Miller CC 3rd, et al: Postoperative risk factors for delayed neurologic deficit after thoracic and thoracoabdominal aortic aneurysm repair: a case-control study. J Vasc Surg 2003; 37: 750-4.
6) Griepp RB,Griepp EB: Spinal cord perfusion and protection during descending thoracic and thoracoabdominal aortic surgery: the collrateral network concept. Ann Thorac Surg 2007; 83: S865-9.
7) Cheung AT, Weiss SJ, McGarvey ML, et al: Interventions for reversing delayed-onset postoperative paraplegia after thoracic aortic reconstruction. Ann Thorac Surg 2002; 74: 413-21.
8) Kaplan JA, Reich DL, Savino JS: Kaplan's cardiac anesthesia-sixth edition: Thoracic aorta. Philadelphia: Elsevier Saunders; 2011. p637-74.